



E-ISSN: 2707-8353  
P-ISSN: 2707-8345  
IJCRO 2022; 4(2): 62-69  
Received: 02-06-2022  
Accepted: 06-07-2022

**Mohammad N Alswerki**  
Division of Special Surgery,  
Department of Orthopedic  
Surgery, Jordan University  
Hospital, Amman, Jordan

**Khaled Mousa**  
Orthopedic Surgery Specialist,  
Private Medical Sector, Jordan  
University Hospital, Amman,  
Jordan

**Bassem Haddad**  
Division of Special Surgery,  
Department of Orthopedic  
Surgery, Orthopedic Surgery &  
Oncology Consultant, Jordan  
University Hospital, Amman,  
Jordan

**Zaina Alhelou**  
Medical Student, Jordan  
University School of Medicine,  
Amman, Jordan

**Shada Al Gharibeh**  
Medical Student, Jordan  
University School of Medicine,  
Amman, Jordan

**Lana AlRaia**  
Intern Doctor, Jordan  
University Hospital, Amman,  
Jordan

**Munther G Al-Saber**  
Orthopedic Surgery Specialist,  
Private Medical Sector,  
Amman, Jordan

**Faris AlShammas**  
Pathology Department,  
Jordan University Hospital,  
Amman, Jordan

**Heyam Awad**  
Pathology Department,  
Jordan University Hospital,  
Amman, Jordan

**Corresponding Author:**  
**Mohammad N Alswerki**  
Division of Special Surgery,  
Department of Orthopedic  
Surgery, Jordan University  
Hospital, Amman, Jordan

## Patellar tendon rupture as a first presentation for undiagnosed primary hyperparathyroidism

**Mohammad N Alswerki, Khaled Mousa, Bassem Haddad, Zaina Alhelou, Shada Al Gharibeh, Lana AlRaia, Munther G Al-Saber, Faris AlShammas and Heyam Awad**

**DOI:** <https://doi.org/10.22271/27078345.2022.v4.i2b.123>

### Abstract

**Introduction:** patellar tendon rupture is usually traumatic in origin; however, spontaneous or atraumatic rupture is uncommon and often signify underlying pathological processes involving the tendon substance. One of these pathological processes is primary hyperparathyroidism.

**Case presentation:** In this case report we present a unique case of a patient not diagnosed previously with hyperparathyroidism. The patient's initial presentation was atraumatic knee pain and knee extension weakness, imaging studies showed complete avulsion of the patellar tendon from its tibial footprint. Another clinical finding was an index finger swelling, which, after laboratory and imaging studies of the parathyroid gland, turned out to be brown tumor of undiagnosed primary hyperparathyroidism. The patient underwent excision of the parathyroid adenoma, and repair of the patellar tendon using semitendinosus tendon graft and intraosseous tibial anchors at the footprint. Patient regained pain-free and good movement of her knee.

**Conclusion:** Atraumatic patellar tendon rupture, especially in the absence of renal impairments should raise the suspicion of pathological process involving the tendon substance, this should alert the orthopedic surgeon to look for secondary causes of degeneration of the tendon substance, of which hyperparathyroidism is an important differential diagnosis.

**Keywords:** Patellar tendon rupture, Knee extensor mechanism rupture, Primary hyperparathyroidism.

### Introduction

Patellar tendon rupture or injury is usually secondary to sport or traumatic injuries. Spontaneous rupture of the patellar tendon/ quadriceps tendon (knee extensor mechanism) is usually secondary to a disease process and histopathological changes involving the substance of the tendon. These pathological changes can be secondary to many systemic diseases, in our case it's related to primary hyperparathyroidism<sup>[4, 6]</sup>. Patellar or extensor mechanism injury usually occur in the setting of established diagnosis of hyperparathyroidism regardless of the etiology (primary, secondary, or tertiary); however, it's very unusual that the rupture event can be the presenting symptom of undiagnosed primary hyperparathyroidism. Previous case reports which shed light to this topic were related to secondary or tertiary hyperparathyroidism linked and induced by end stage renal disease or chronic kidney disease<sup>[3, 2, 7]</sup>. However, in this case we link the condition to primary hyperparathyroidism. Moreover, according to the authors best knowledge, no previous reported cases exist in the literature. In this case report we highlighted the importance of considering the possibility of hyperparathyroidism in patients presenting with spontaneous patellar tendon rupture.

### Case Presentation

#### History and physical examination

Our patient is 38 years old female patient, not known to have any medical conditions or endocrine pathologies. The patient presented to the clinic complaining of left knee pain and weakness of 2 months duration. No previous history of trauma. Pain was progressive and affected her normal walking. She was unable to extend and straighten her knee. Interestingly, patient reported right index finger swelling and pain since a couple of months. Her exam was remarkable only for loss of extensor mechanism of the left knee and right index finger pain and fusiform swelling.

**Diagnostic studies: Imaging and laboratory assessment**

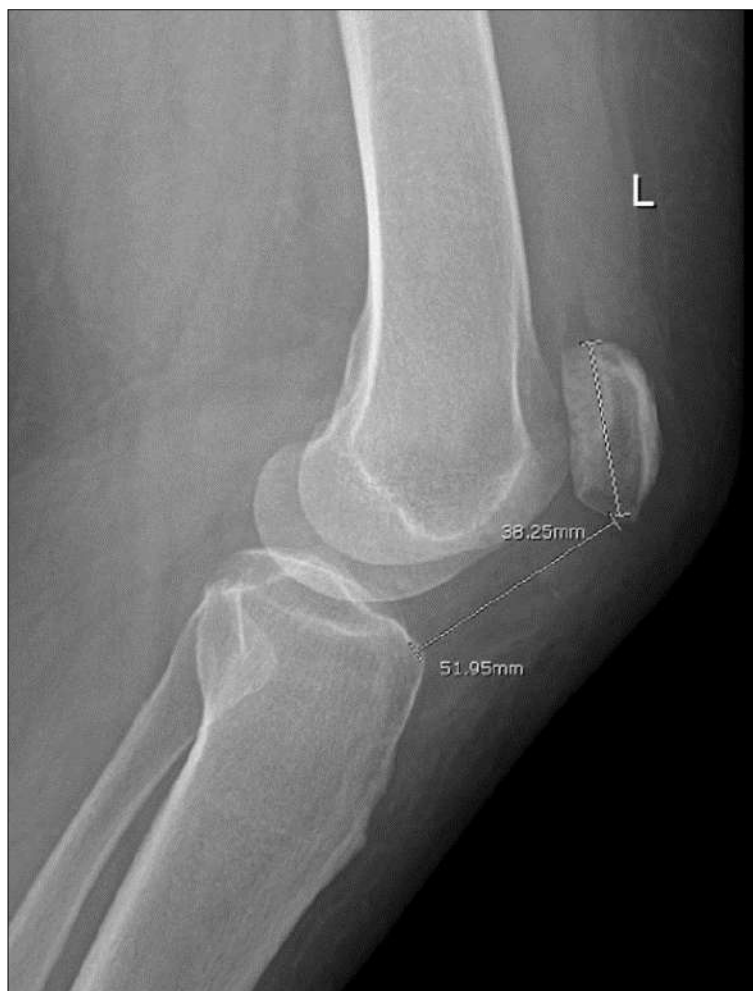Preoperative imaging was done to evaluate her left knee and right index finger. The pre-operative knee radiography showed patella alta with high Insall-Salvati ratio of (1.36) (Figure 1). Imaging of the patient right index finger showed lytic expansile lesion involving all the proximal phalanx with cortical thinning and ballooning (Figure 2). Laboratory studies were normal except for elevated serum calcium levels and extremely high parathyroid hormone level. She underwent neck ultrasound which showed two hypoechoic nodules in the right thyroid lobe characterized by being spongiform, hypoechoic, wider than taller, with smooth foci, the first was sized 4X7 mm, and the other 5X3 mm.

She also underwent 99mTc-Sestamibi scan using pinhole collimator which showed an area of increased uptake adjacent to the inferior pole of the right thyroid lobe (Figure 3) that persisted on delayed 99mTc-Sestamibi image.

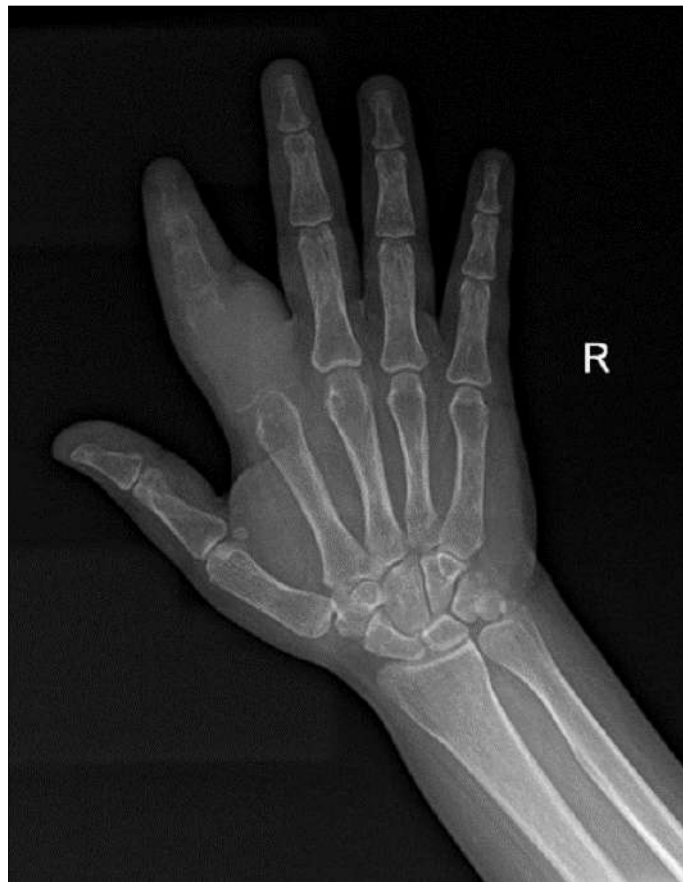The patient underwent bone scintigraphy which showed increased uptake of the right wrist and proximal phalanx of the index finger (Figure 4), as well as a small uptake in the left iliac bone (Figure 5) as, a diagnosis consistent with brown tumor of hyperparathyroidism. Left knee MRI of the patient showed complete rupture of the patellar tendon from its tibial attachment (Figure 6). Right index finger MRI showed circular multiple septate mass dorsally (Figure 7).

**Table 1:** The patient laboratory profile preoperatively was as following.

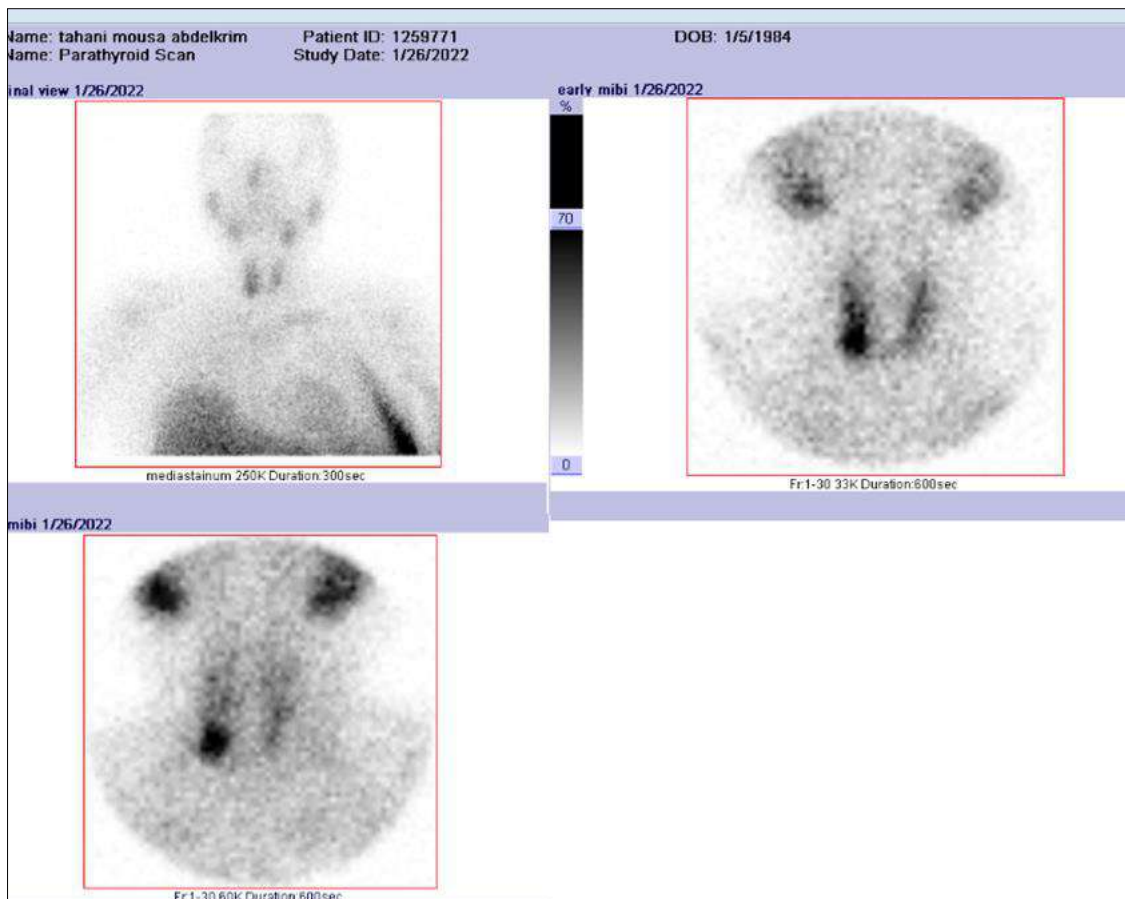
| Complete Blood Count (CBC)   |                         | Serum Chemistry |           | Metabolic bone work-up |            |
|------------------------------|-------------------------|-----------------|-----------|------------------------|------------|
| Hemoglobin (Hb)              | 12.3 g/dL               | Sodium          | 139 mg/dL | Calcium                | 10.6 mg/dL |
| White Blood Cell Count (WBC) | 7.4 g/dL                | Potassium       | 4.4 mg/dL | Phosphorus             | 2.2 mg/dL  |
| Platelet count (PLT)         | 369 x10 <sup>9</sup> /L | Magnesium       | 2.1 mg/dL | Parathyroid hormone    | 1053 pg/ml |
| Neutrophils percent          | 69%                     | Creatinine      | 0.4 mg/dL |                        |            |
| Lymphocyte percent           | 25.7%                   | Urea            | 18 mg/dL  |                        |            |



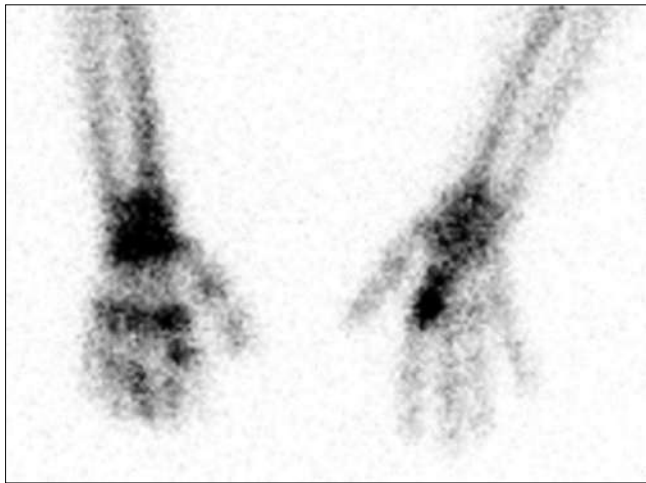**Fig 1:** Left knee lateral X-Ray showing evident patella Alta. Insall-Salvati ratio is equal to 1.36 (Patellar tendon length 51.95 divided by Patellar bone length 38.25).



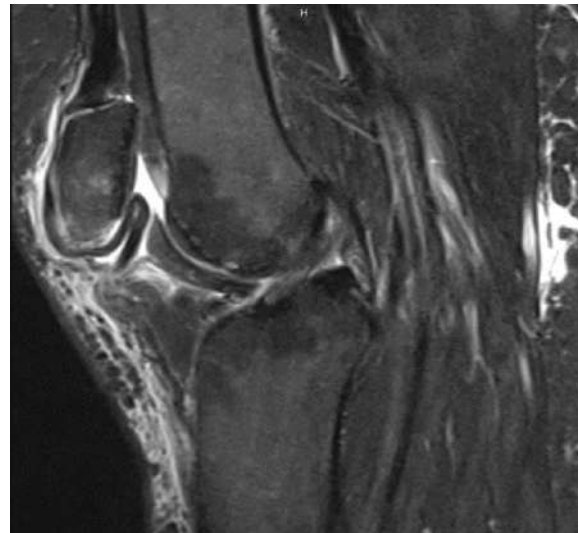
**Fig 2:** Right hand AP X-ray showing ulnar sided ill-defined soft tissue swelling of the right index finger. It shows obvious obliteration of bony landmarks of the proximal phalanx of the index finger with evident circumferential cortical destruction along the whole length of the proximal phalanx. MCPJ and PIPJ of the same phalanx are not involved yet they look arthritic. Generalized osteopenia is noted in the other phalangeal and metacarpal bones.



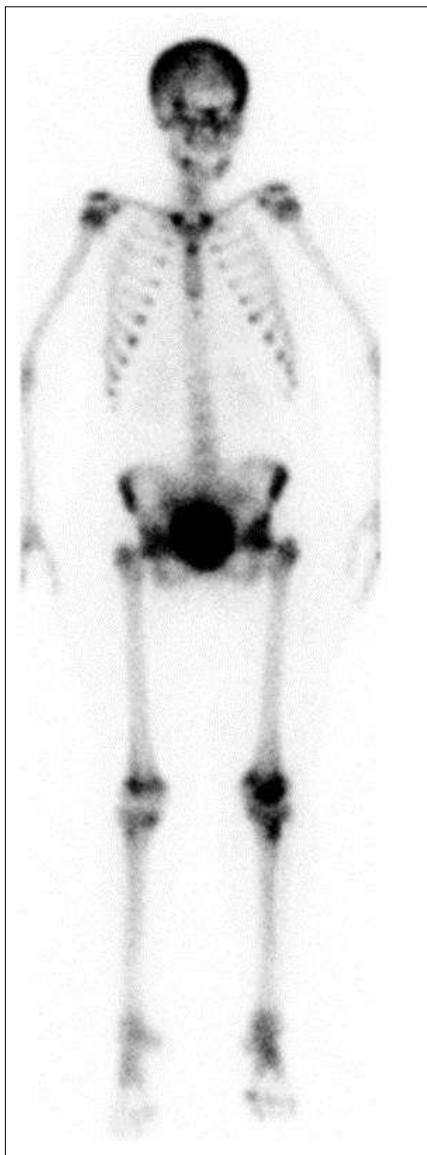**Fig 3:** Sestamibi parathyroid scan showing bilateral areas of increased uptake with evident focal uptake over the inferior right parathyroid gland.



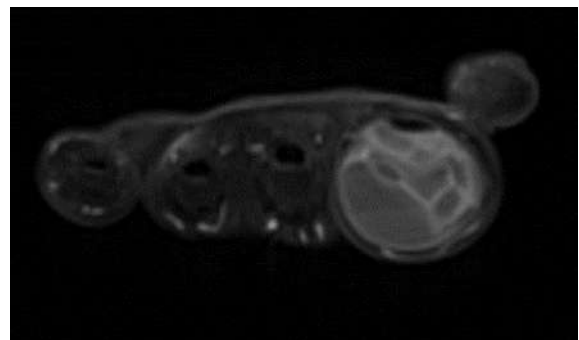
**Fig 4:** Bone scan of bilateral hand and wrist joints is illustrated. The left side shows focal uptake at the area of the proximal phalanx and metacarpal of the second finger with associated generalized signal over the wrist joint. On the right side, signal appears more intense over the wrist joint with associated dispersed uptake over the MCP and IP joints.



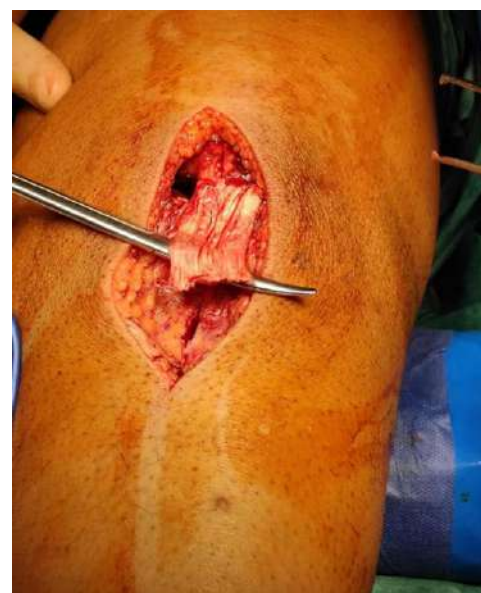**Fig 6:** Sagittal view T2 MRI of the left knee showing mid-substance patellar tendon rupture with evident retraction and folding at the articular surface of the patella. Minimal fluid signal is noted inside the joint. Evident periarticular hypo-intense signal is seen at both the femoral and tibial sides.



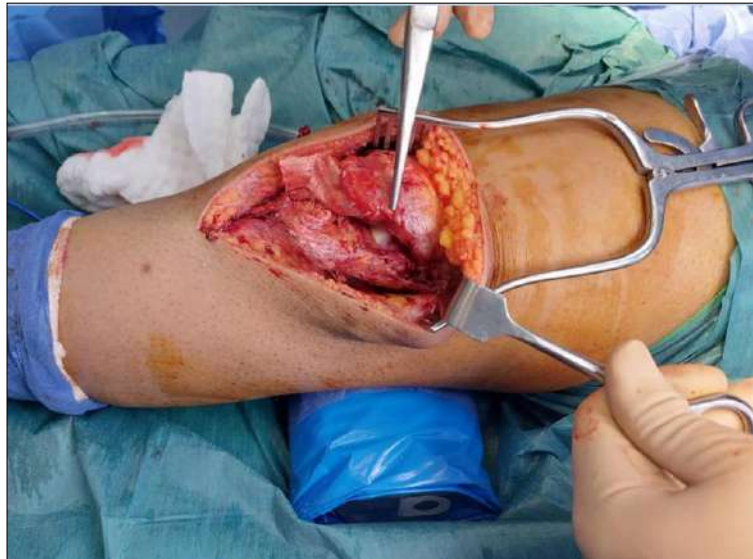
**Fig 5:** Bone scan of the whole body shows areas of increased uptake over the skull, bilateral shoulder and hip joints, iliac crests and focal signal over the left knee joint.



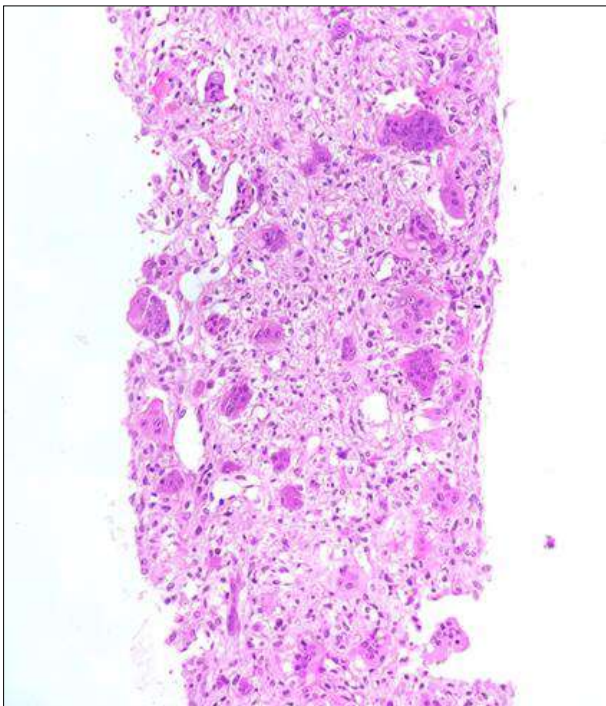
**Fig 7:** T2 MRI showing an axial view of the right hand with evident hypointense well-defined circular mass with multiple septations. The mass is located at the dorsal aspect of the index finger causing flattening and volar displacement of the flexor tendon.



**Fig 8:** This is clinical photo of the left knee showing a longitudinal skin incision over the patella. Intra-operative finding of a complete mid-substance rupture of the patella tendon is noted. Evident fraying of tendon end can be appreciated as well.



**Fig 9:** Patellar tendon rupture is noted to involve the whole lateral aspect of the retinaculum. Self-retaining retractor is placed over the proximal aspect of the wound.



**Fig 10:** Multiple multinucleated giant cells diffusely arranged in a fibro-cellular stroma (Hematoxylin and eosin, 100X).

**Management**

After completion of the diagnostic work-up, the patient underwent surgical reconstruction of the left patellar tendon. Intraoperative findings were consistent with the MRI findings with complete avulsion of the patellar tendon from its footprint in the tibia (Figure 8, 9). Reconstruction was done via a semitendinosus tendon autologous graft and augmented by anchors and Ortho-cord [DuPuy] sutures which were fixed through a bone tunnel in the tibial footprint of the patellar tendon. The patient was kept in a cast for 6 weeks. A biopsy was taken from the right index finger at the same session for confirmation of the diagnosis. The patient was then referred to the endocrine surgery unit where she underwent right inferior total parathyroidectomy. Intraoperative frozen section biopsy was sent and was confirmed to be parathyroid adenoma before full excision.

**Follow-up**

At follow-up visits in the clinic patient showed good healing at both surgery site in the neck and the knee. The cast was changed to a hinged knee brace for 6 weeks, then it was removed. Knee pain was resolved and muscle power was excellent. The patient restored near full range of motion. Regarding the parathyroid adenoma, the patient’s blood labs improved after the surgery, and there were no reported complications.

**Table 2:** The patient laboratory profile postoperatively was as following

| Complete Blood Count (CBC)   |                         | Serum Chemistry |            | Metabolic bone work-up |           |
|------------------------------|-------------------------|-----------------|------------|------------------------|-----------|
| Hemoglobin (Hb)              | 11.9 g/dL               | Sodium          | 139 mg/dL  | Calcium                | 9.1 mg/dL |
| White Blood Cell Count (WBC) | 5.9 g/dL                | Potassium       | 4.6 mg/dL  | Phosphorus             | 3.3 mg/dL |
| Platelet count (PLT)         | 339 x10 <sup>9</sup> /L | Magnesium       | 2.4 mg/dL  | Parathyroid hormone    | 199 pg/ml |
| Neutrophils percent          | 64%                     | Creatinine      | 0.42 mg/dL |                        |           |
| Lymphocyte percent           | 28%                     | Urea            | 16.9 mg/dL |                        |           |

**Histopathology**

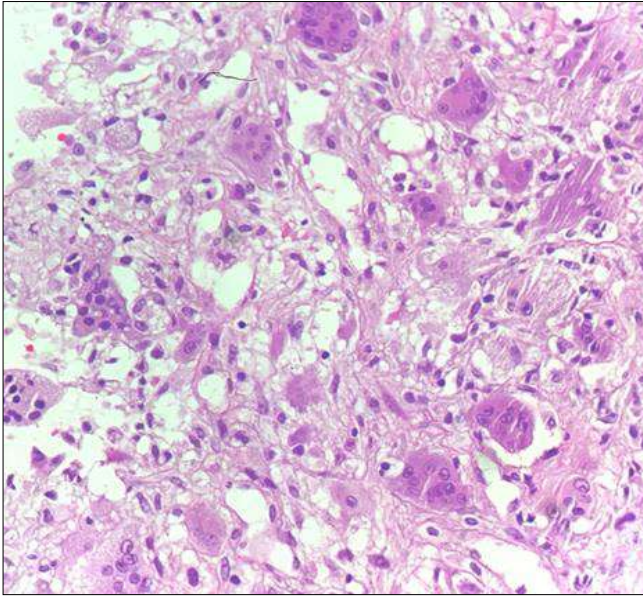
Histopathological examination of the right index finger lesion specimen was done. Microscopic examination revealed numerous multinucleated osteoclast-type giant cells arranged in a diffuse pattern in a fibro-cellular stroma containing bland round to oval mononuclear cells (Figure 10, 11). In addition, focal bone remodeling was also observed (Figure 12). No evidence of prominent atypia,

necrosis or increased mitotic activity was identified in the examined sections.

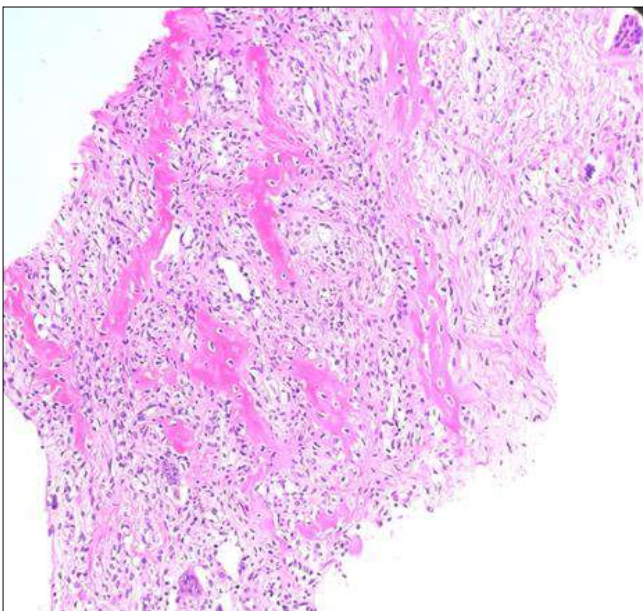
As for the parathyroid adenoma, the gland was 2.5 cm in greatest dimension and weighed 1.6 grams. Microscopic examination revealed a well-circumscribed mass replacing the normal parathyroid tissue. The mass consisted predominantly of a cellular proliferation of uniform small chief cells with small round nuclei and amphophilic to clear

granular cytoplasm arranged in nests along with fewer oxyntic cells exhibiting abundant eosinophilic cytoplasm (Figure 13). Moreover, the mass did not contain any adipocytes (Figure 14).

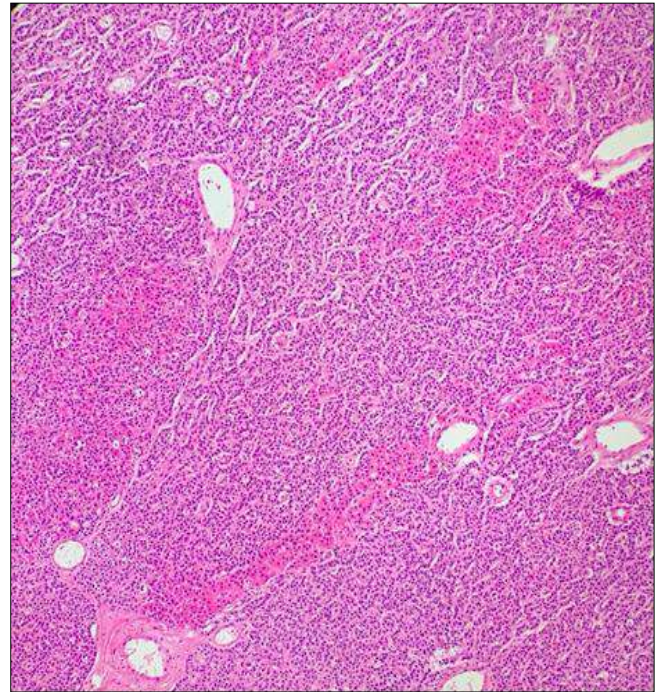
A rim of a normal parathyroid gland was identified at the edge of the mass. No evidence of capsular invasion, prominent nuclear atypia, necrosis, or notable mitotic activity were identified in the examined sections (Figure 15). Therefore, the diagnosis of parathyroid adenoma was confirmed.



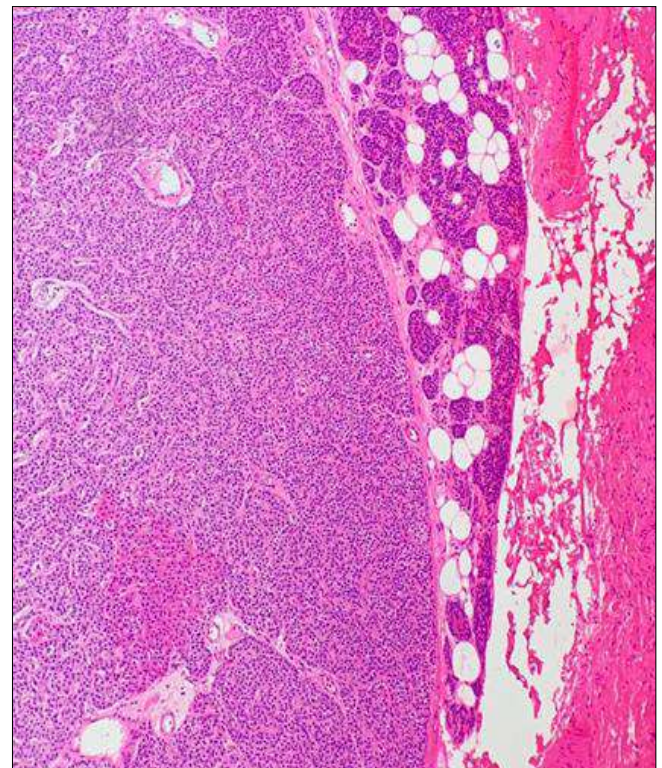
**Fig 11:** Multiple multinucleated giant cells diffusely arranged in a fibro-cellular stroma (Hematoxylin and eosin, 400X).



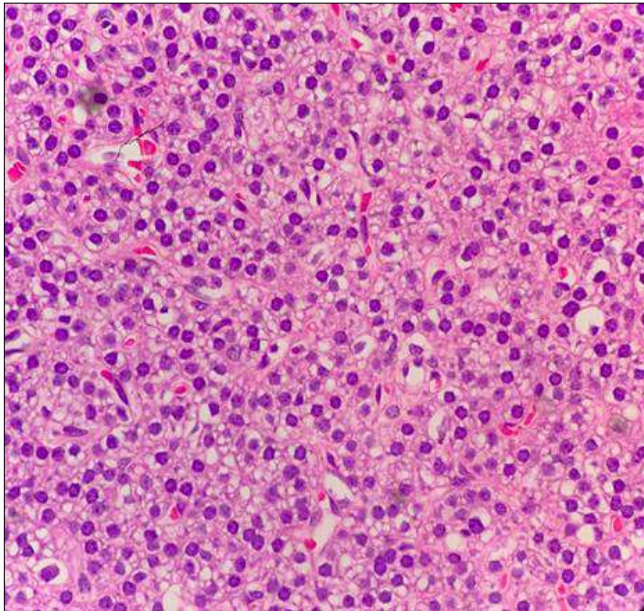
**Fig 12:** An area exhibiting reactive bone formation (Hematoxylin and eosin, 100X).



**Fig 13:** The parathyroid mass contains a proliferation of cells arranged in nests, unremarkable blood vessels are also present (Hematoxylin and Eosin, 100X).



**Fig 14:** The mass at the left half of the picture is seen compressing the normal parathyroid tissue at the right side of the picture. Note how the mass lacks any adipocytes compared to the normal parathyroid tissue (Hematoxylin and Eosin, 100X).



**Fig 15:** High power view of the mass shows that the chief cells contain uniform small round nuclei and lack any features of malignancy (Hematoxylin and Eosin, 600X).

### Discussion and literature review

A spontaneous tendon rupture is defined as a rupture that happens while moving or engaging in activities that typically do not damage the musculotendinous units [1]. Patellar tendon rupture is rare as a healthy tendon that does not have any histopathologic abnormalities does not spontaneously rupture. Additionally, a number of systemic disorders, steroids, and microtrauma are usually linked to patellar tendon rupture [1, 5].

In a study done by Seng et al., the researchers studied the spontaneous disruption of the bilateral knee extensor mechanism, the patient included in the report had a right patellar tendon rupture and a left quadriceps tendon rupture. He underwent primary repair of both tendons. Postoperatively, he followed a strict physiotherapy regimen and achieved good functional outcome [5]. In a case report done by Chen et al., the researchers studied the spontaneous bilateral tendon rupture in primary hyperparathyroidism. The patient revealed tenderness in both knees and proximal displacement of both patellae. Repair was accomplished by drilling three holes from the inferior pole of the patella through the patella proximally and suturing the ruptured tendon to the bone [1]. In another report done by Zabala et al., a patient presented with bilateral rupture of the extensor mechanism of the knee in which a tertiary hyperparathyroidism was previously diagnosed. The studied patient has end stage renal disease and was on regular hemodialysis, repair of the tendons was accomplished using heavy nonabsorbable sutures, maintaining the original insertional point in order to avoid tilting of the patella [9].

As shown, multiple articles studied the potential relationship between systemic diseases which include hyperparathyroidism and renal diseases with quadriceps and patellar tendon rupture [5, 9]. In other case reports, it was secondary and tertiary hyperparathyroidism with renal disease, while in our case, it's primary hyperparathyroidism [5, 9]. Moreover, as mentioned in the previous literature, patients with rupture incidents either traumatic or non-traumatic usually have being previously diagnosed with hyperparathyroidism, in our case report, the rupture event

was the initial presenting symptom [1, 5, 8]. Also, patellar tendon rupture is mostly bilateral in previous literature, on the other hand, this case is unilateral patellar tendon rupture [1, 5].

### Conclusion & Clinical Message

Atraumatic patellar tendon rupture, especially in the absence of renal impairments should raise the suspicion of pathological process involving the tendon substance, this should alert the orthopedic surgeon to look for secondary causes of degeneration of the tendon substance, of which a hyperparathyroidism is an important differential diagnosis.

### Consent

The patient included in this study voluntarily agreed on the inclusion of materials in this work by signing a written consent form. The informed consent explained the premise of this report, the state of his anonymity within the report and the confidentiality of her personal information.

### Competing interest

The authors declare no conflict of interest.

### Funding

This report did not receive any specific grant from funding agencies in the public, commercial, or not-for-profit sectors.

### Data availability statement

The authors confirm that data for the findings used for generation of this case report is available within the article.

### Acknowledgment

We would like to show our gratitude to our authors for their commitments for sharing their pearls of wisdom with us during the course of this research report.

### Authors contribution

M A wrote the introduction, the clinical presentation, the discussion, and the abstract. KM, BH participated in the writing of the discussion, BH also revised the final form of the report. ZA, SA, LA participated in the discussion, abstract, gathering data and images from the patient and health record system. M A wrote the figure's description, FA participated in the pathological slide's description.

### References

1. Chen CH, Niu CC, Yang WE, Chen WJ, Shih CH. Spontaneous bilateral patellar tendon rupture in primary hyperparathyroidism, *Orthopedics*. 1999;22(12):1177-1179.
2. Gao MF, Yang HL, Shi WD. Simultaneous bilateral quadriceps tendon rupture in a patient with hyperparathyroidism undergoing long-term haemodialysis: A case report and literature review. *J Int. Med. Res.* 2013;41(4):1378-1383.
3. Grecomoro G, Camarda L, Martorana U. Simultaneous chronic rupture of quadriceps tendon and contra-lateral patellar tendon in a patient affected by tertiary hyperparathyroidism. *J. Orthop. Traumatol.* 2008;9(3):159-162.
4. Moretti B, Notarnicola A, Moretti L, Garofalo R, Patella V. Spontaneous bilateral patellar tendon rupture: a case report and review of the literature, *Chir. Organi*

- Mov. 2008;91(1):51-55.
5. Seng C, Lim YJ, Pang HN. Spontaneous disruption of the bilateral knee extensor mechanism: A report of two cases. *J. Orthop. Surg.* 2015;23(2):262-266.
  6. Steiner CA, Palmer LH. Simultaneous bilateral rupture of the quadriceps tendon. *Am. J. Surg.* 1949;78(5):752-755.
  7. Stokey PJ. American Journal of Surgery and Clinical Case Reports Case Report Bilateral Patellar Tendon Rupture in a Patient with Uncontrolled Primary Hyperparathyroidism: A Case Report Citation: Stokey PJ. Bilateral Patellar Tendon Rupture in a Patient with Uncontrolled Primary Hyperparathyroidism: A Case Report, *Ame J Surg Clin Case Rep.* 2022;4(9):1-4.
  8. Tandogan RN, Terzi E, Gomez-Barrena E, Violante B, Kayaalp A. Extensor mechanism ruptures, *EFORT Open Rev.* 2022;7(6):384.
  9. Zabala, *et al.* Simultaneous and spontaneous rupture of patellar tendon and contralateral quadriceps tendon in a patient with tertiary hyperparathyroidism: A case report, *Int. J. Case Reports Images.* 2013;3(8):13-16.