



E-ISSN: 2707-8353

P-ISSN: 2707-8345

IJCRO 2020; 2(1): 12-14

Received: 13-04-2020

Accepted: 14-05-2020

Dr. Diwakar Pratap

Senior Resident, Department of Orthopedics, Himalayan Institute of Medical Sciences, Swami Rama Himalayan University, Dehradun, Uttarakhand, India

Dr. R Maheshwari

Professor & Head Department of Orthopedics, Himalayan Institute of Medical Sciences, Swami Rama Himalayan University, Dehradun, Uttarakhand, India

Dr. Digvijay Aggarwal

Assistant Professor, Department of Orthopedics, Himalayan Institute of Medical Sciences, Swami Rama Himalayan University, Dehradun, Uttarakhand, India

Dr. Smita Chandra

Professor, Department of Pathology, Himalayan Institute of Medical Sciences, Swami Rama Himalayan University, Dehradun, Uttarakhand, India

Corresponding Author:

Dr. Diwakar Pratap

Senior Resident, Department of Orthopedics, Himalayan Institute of Medical Sciences, Swami Rama Himalayan University, Dehradun, Uttarakhand, India

Fibrosarcoma of hip: An Unusual Presentation

Dr. Diwakar Pratap, Dr. R Maheshwari, Dr. Digvijay Aggarwal and Dr. Smita Chandra

DOI: <https://doi.org/10.22271/27078345.2020.v2.i1a.15>

Abstract

Fibrosarcoma is a malignant tumor of fibroblasts. At one time, it was considered one of the most common soft tissue sarcomas. However, the diagnosis of fibrosarcoma is made much less frequently today because of the recognition and separate classification of other spindle cell lesions that have similar microscopic features. Here, we are presenting a case of fibrosarcoma of hip, which is uncommon at this site.

Keywords: Fibrosarcoma, soft tissue sarcoma, hip swelling

Introduction

Fibrosarcoma had been found to be a highly malignant tumour of the mesenchymal cells. Histologically fibrosarcoma has an excessive splitting rate of the spindle cell fibroblast [1, 2]. It has also been found to be one of the rare tumours of the mesenchymal cells. They are of 2 types Primary and secondary, Primary fibrosarcoma arises within the medullary canal of the bone [3]. Secondary fibrosarcoma results from the pre-existing bone lesions or it can also result from radiotherapy induction to the bone [4]. Treatment of fibrosarcoma via radiotherapy and chemotherapy has been found to be very low but still being used as a neoadjuvant and/or adjuvant tumor treatment. We are presenting a case of rare condition of hip joint – a diagnostic dilemma.

Case report

A 20 years old female came to our OPD with complaint of pain over left hip region since 2 months and difficulty in squatting and sitting cross legged since 1 month. There was a history of trauma (Fall on ground) about 4 months back. During this course of time she had few (3-4) episodes of low grade fever, for which she took antipyretic and was relieved of the symptoms.

For the 10 days the intensity of the pain has significantly increased and was not relieved from rest / analgesic medication. She was unable to squat/ sit cross legged. She also noticed a swelling over left hip region.

On examination there was a non fluctuant firm swelling about 5cm x 5cm present over posterior-lateral aspect of left hip. The swelling was tender with mild local rise of temperature. The left hip movements (Abduction / Flexion/ Internal and External rotation) was painful. Her blood investigation ESR:51, CRP: 9.61, TLC 9500.

To rule out infective cause, under aseptic condition 5 ml of haemorrhagic fluid was aspirated and sent for C/S. Till the C/S report we started her on empirical antibiotic (Linezolid), and advised for MRI of pelvis with bilateral hip joint. C/S suggestive of No growth, while MRI report suggestive of a well defined lesion with multiple differential intensity fluid levels along the posterior aspect of neck of left femur with extension into myofascial plane in left hamstring muscles ? Haematoma/ Detached Aneurysmal bone cyst (Fig 1).

To investigate further patient was planned for excision biopsy. Through postero-lateral approach to hip the swelling was exposed. Per operatively the cystic mass was arising from posterior aspect neck of the femur and extending towards greater sciatic notch and ischial tuberosity. The mass was excised in toto measuring (9cm x 5cm) and on dissection there was haemorrhagic fluid filled sac. The excised mass was sent for Histopathological analysis Fig 2.

Histopathology report was suggestive of intermediate to high grade sarcoma with features suggestive of fibrosarcoma. On further immunohistochemistry analysis it was positive for Vimentin, CD34 (Fig 3). Patient was referred to cancer institute for further management.

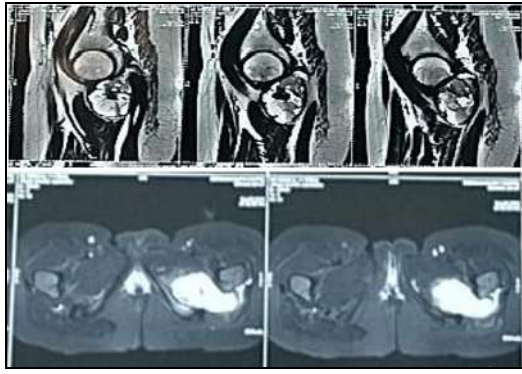


Fig 1: MRI suggestive of a well defined lesion with multiple differential intensity fluid levels along the posterior aspect of neck of left femur with extension into myofascial plane in left hamstring muscles? Haematoma/ Detached Aneurysmal bone cyst.

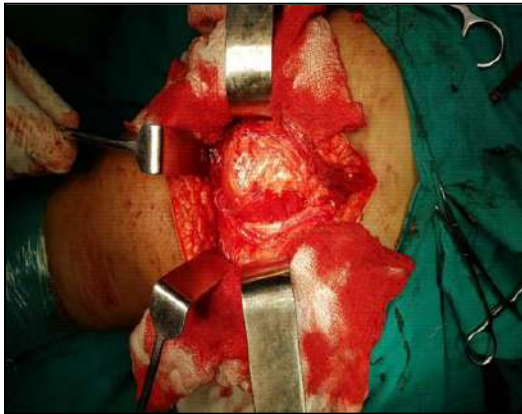

Fig 2: Soft tissue mass exposed extending into left hip joint.

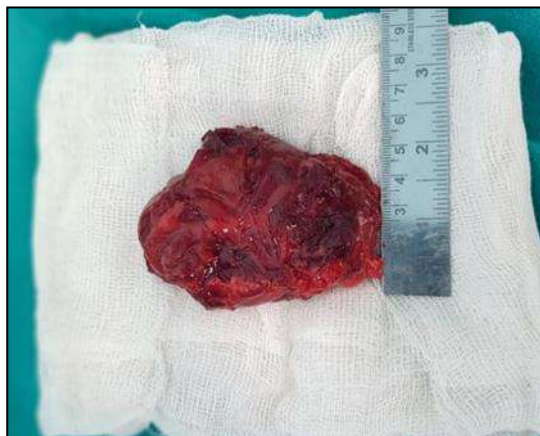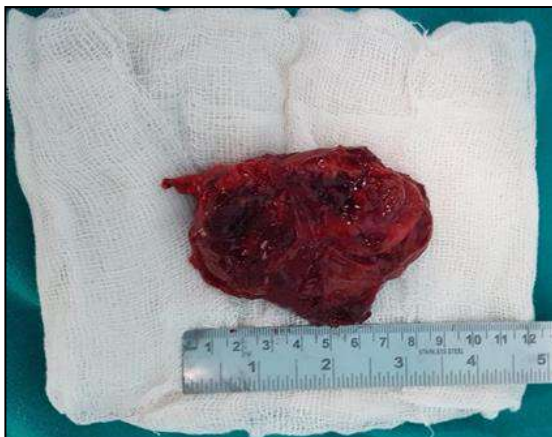


Fig 3: The excised tissue mass measuring 7cm x 5cm.

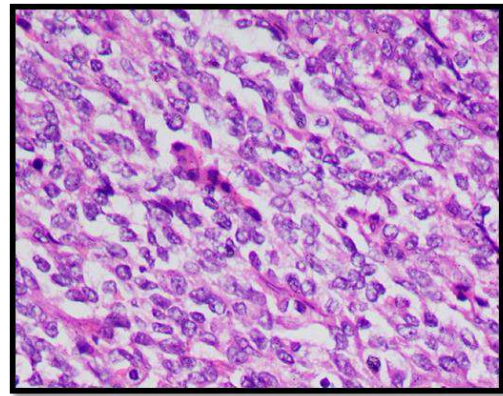


Fig 4: Histopathology Slide

Discussion

Fibrosarcoma is a malignant tumor that arises from the fibroblasts. Weiss SW *et al* in their study on soft tissue neoplasm stated “This tumor has been greatly over diagnosed and this diagnosis has been frequently applied to virtually any richly cellular, collagen-forming spindle-cell tumor including malignant fibrous histiocytoma, malignant peripheral nerve sheath tumor and a host of other sarcomatous and pseudosarcomatous lesions”^[5]. Aggouris K *et al.* described about fibrosarcoma that “Clinically the most common sign is a local, progressive mass with no discrete borders in distal part of extremities. In some cases, the surface is necrotic or ulceric which makes the appearance similar to vascular malformations like hemangioma”^[6]. Unlike in our patient the swelling over left hip region was slow progressive without any surface characterizing feature. Lee MJ *et al.* found that “MRI is a good choice for better evaluation in diagnoses and follow-up of soft tissue masses. MRI is considered the modality of choice for evaluation of the diseases in the extremities, head, neck and pelvis”^[7, 8]. Similarly in our case until MRI was done it was considered to be traumatic haematoma.

Radiological imaging of fibrosarcomas reveals radiolucent lesions with a geographical, moth-eaten or permeative pattern of bone destruction^[9]. In Contrast to our case there was no bony lesion seen over left hip which made us think otherwise.

Conclusion

In our country where infection is more common, underlying hip pain with swelling in young age, infection is most common differential diagnosis. However like in our case where radiological features are suggestive of haematoma/ detached aneurysmal bone cyst. It is advisable to do open biopsy and possibility of tumour should be kept in mind.

References

1. Dickey ID, Fibrosarcoma MD. <http://emedicine.medscape.com/article/1257520-overview#a0104>.
2. Arora K. Soft tissue Tumors - Fibrosarcoma of soft tissue - adult. <http://www.pathologyoutlines.com/topic/softtissuefibrosarcoma.html>.
3. Thomson AD, Turner-Warwick RT. Skeletal sarcomata and giant-cell tumour. The Journal of bone and joint surgery. 1955; 37:285-290.
4. Angiero F, Rizzuti T, Crippa R, Stefani M.

- Fibrosarcoma of the jaws: two cases of primary tumors with intraosseous growth. *Anticancer research*. 2007; 27:2573-2581.
5. Weiss SW, Goldblum JR. *Enzinger and Weiss's Soft Tissue Tumors*. 5th ed. Elsevier: New Delhi. Fibrosarcoma, 2008, 303-30.
 6. Aggouris K, Brilakis E, Giokas A. Infantile fibrosarcoma and infantile fibromatosis diagnosis and treatment clinical presentation of three cases. *EEXOT*. 2008; 59:170-75.
 7. McCarville MB, Kaste SC, Pappo AS. Soft-tissue malignancies in infancy. *AJR Am J Roentgenol*. 1999; 173(4):973-7.
 8. Lee MJ, Cairns RA, Munk PL, Poon PY. Congenital-infantile fibrosarcoma:magnetic resonance imaging findings. *Can Assoc Radiol J*. 1996; 47(2):121-5.
 9. Theodorou DJ, Theodorou SJ, Sartoris DJ. Primary non-odontogenic tumors of the jawbones. An overview of essential radiographic findings. *J Clin Imag*. 2003; 27:59-70. doi: 10.1016/S0899-7071(02)00518-1.