



E-ISSN: 2707-8353
P-ISSN: 2707-8345
IJCRO 2020; 2(1): 15-17
Received: 14-04-2020
Accepted: 15-05-2020

Amalina Anuar
MBBS, Clinical Research
Centre, Hospital Tuanku
Fauziah, Perlis, Ministry of
Health, Malaysia

Misdiagnosis of postpartum lower back pain: Report of a rare septic arthritis

Amalina Anuar

DOI: <https://doi.org/10.22271/27078345.2020.v2.i1a.16>

Abstract

Sacroiliac septic arthritis is an osteoarticular infection of the sacroiliac joint caused by various microorganisms, often bacterial. This report a case of postpartum septic sacroiliitis. On day six postpartum, a young mother presented with sudden onset of severe lower back pain, radiating to her left gluteal, following an uncomplicated vaginal delivery. Unable to weight bear, she was rendered immobile. X-ray findings were inconclusive. She was treated for prolapsed intervertebral disc and discharged. With no signs of improvement, three weeks later, at day 27 postpartum, an outpatient magnetic resonance imaging of spine and pelvis revealed left sacroiliac septic arthritis. Positive septic workup supported imaging findings. Definitive treatment was commenced. Within two months, the pain improved and she steadily mobilized again. Nonetheless, she still had residual pain likely due to possible joint destruction and/or fusion. She was managed appropriately. A year later, the pain was still there. In conclusion, better understanding of disease matter, right imaging tools for disease detection and high index of suspicion are paramount to avoid misdiagnosis. Management should surpass medical/surgical treatment, especially for those with poor prognosis. We should focus on improving patient's quality of life apart from treating the actual disease.

Keywords: sacroiliac septic arthritis, septic sacroiliitis, septic arthritis, lower back pain, postpartum, case report

Introduction

The sacroiliac (SI) joint is a compound synovial and syndesmotic joint. It provides stability and supports the entire weight of the upper body. Due to hormonal, physiological and anatomical changes amid pregnancy, the risk of developing musculoskeletal disorders are higher. During pregnancy, the hormone relaxin induces relaxation of fibrous tissue leading to increased mobility of the pelvic structure, which causes recurrent micro-trauma, exposing joint surfaces to infection during transient bacteraemia^[1].

SI septic arthritis is an osteoarticular infection of the SI joint caused by various microorganisms; commonest is bacterial, accounting about >95% of all infections^[2]. Although septic arthritis is common, SI septic arthritis is rare, representing only 1-2% of all cases of septic arthritis^[3]. Poor vascularization consequently decreasing risk of haematogenous spread might explain the low number of cases.

Symptoms are generally non-specific. Due to this, this disabling condition might be mistaken with other more common conditions. Quick detection is utmost important as it can cause rapid joint destruction, substantial morbidity and in some cases; mortality. This case report describes a case of a rare septic arthritis which was initially missed due to certain unavoidable factors.

Case Report

With no underlying medical illness, at day six postpartum, an (at that time) 28-year-old Para 2+1 presented with sudden onset of progressively worsening severe lower back pain, radiating to her left lower limb and associated with heaviness over left leg. Pain score was 10/10. Unable to weight bear due to pain, she was rendered immobile.

Upon further questioning, she was a medical staff. There was no history of fall, trauma, past injuries, infections or surgeries. The birth was an uneventful spontaneous vaginal delivery to a healthy baby girl. Throughout the pregnancy, she attended regular antenatal follow-ups. Besides mild anemia in pregnancy and maternal obesity with Body Mass Index (BMI) of 37.6kg/m², the pregnancy progressed well without any complications. She admitted having history of intermittent, non-specific, mild lower back pain since her first childbirth, 3 years ago but she did not seek any medical treatment as it was tolerable and it does not interfere with her mobility. Upon physical examination, the patient was afebrile but there was tenderness over lumbosacral and left gluteal region. Hip range of motion was limited.

Corresponding Author:
Amalina Anuar
MBBS, Clinical Research
Centre, Hospital Tuanku
Fauziah, Perlis, Ministry of
Health, Malaysia

Straight leg raising (SLR) test was positive. Else, review of other systems was normal. White blood cell (WBC) count was raised ($19.18 \times 10^3/\mu\text{L}$) and X-ray of spine and pelvis was inconclusive. At this point of time, history, physical examination and investigation suggested prolapsed intervertebral disc (PID). She was admitted for pain management of PID, prescribed T. Gabapentin 300mg tds, C. Celecoxib 200mg bd/prn, T. Paracetamol 1g qid/prn, Ketoprofen patch LA bd and discharged six days later. At that time, no other biomarkers were taken or repeated. Upon discharge, the pain had minimally reduced with analgesics but she was still unable to ambulate without a walking frame. An outpatient Magnetic Resonance Imaging (MRI) appointment for MRI spine to evaluate her PID was given two weeks post discharge and planned to be reviewed two weeks later.

The outpatient MRI was done on day 27 postpartum. Upon completion of MRI spine, the radiologist noted an abnormality hence continued with MRI pelvis. Urgent review of the MRI images revealed left SI septic arthritis (Fig. 1) with no evidence of PID. She was immediately referred to the Orthopaedic Department on the same day.

By then, she was still unable to ambulate. The pain had worsened and there was new complaint of left gluteal swelling (4cm x 5cm) at the upper outer region which turned out to be a subcutaneous abscess (Fig. 2), most likely from improper intramuscular Diclofenac injection received three weeks prior, during her initial admission.

She was re-admitted. A revised diagnosis of left SI septic arthritis with left gluteal abscess was made. Elevated inflammatory biomarkers supported the diagnosis. C-Reactive Protein was 60mg/L, Erythrocyte Sedimentation Rate; 115mm/Hr, while WBC count was $12.06 \times 10^3/\mu\text{L}$. Blood culture showed no growth. For the gluteal abscess, attempts to evacuate the pus using a large bore branula were unsuccessful. She completed 14 days of high dose intravenous cefuroxime (750mg tds) before conversion to oral cefuroxime (500mg bd) for another 28 days at home. The patient responded well to the pharmacotherapy. Aspiration of the septic arthritis was not attempted. She was subjected to physiotherapy, active mobilization and advised to lose weight.

Within two months, the pain improved and she mobilized again; initially with crutches and eventually independently. Nevertheless, she still had residual pain due to possible joint destruction and/or fusion. She was prescribed analgesics and light duty during the follow-ups. A year later, the now pregnant Gravida 4, Para 2+1 suffers from chronic pain requiring resting the affected joint and taking analgesics when necessary. She had loss more than ten kilograms but then admits it was difficult as most physical activities worsen her pain. An MRI was not repeated for her but an ultrasound pelvis done detected no abnormality. Since then, she has defaulted follow-up.

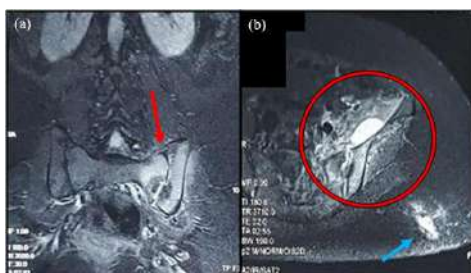


Fig 1: MRI of lumbosacral and pelvis in coronal view (1a) and pelvis in sagittal view (1b) showing the left sacroiliac septic arthritis (red arrow & circle) and left gluteal abscess (blue arrow).

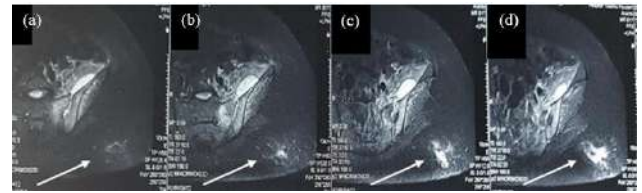


Fig 2: Serial MRI pelvis in sagittal view (2a – 2d) depicting a gluteal collection/ abscess (white arrow) measuring 4.6 cm x 3.0 cm x 3.6 cm.

Discussion

There were many loop holes in this case. A lot of investigations and procedures were either not done or overlooked. The actual source of the infection was not investigated. In this case, the source of infection will remain unknown. It could be from a mild thrombophlebitis she might acquire during admission for delivery or maybe from a more serious source such as from the bacteria *Mycobacterium Tuberculosis*. For her, we may never know. This patient was misdiagnosed during the early onset of the illness. Her sudden un-triggered inability to walk and overwhelming pain were red flags that were ignored thus resulting in initial misdiagnosis. This led to treatment delay and unfavorable prognosis. Treatment initiated after day six of illness will usually prompt poor prognosis^[4]; like in this patient who started treatment on day 22 of illness. Infective biomarkers were also not taken during the first admission, leading the treating team to exclude any possible infective or inflammatory causes.

In this report, the MRI findings had indirectly “saved” the patient. It proves to be superior compared to plain radiography by providing a more detailed evaluation of the SI joint and surrounding soft tissue. Without proper pelvic evaluation, the pathology would be missed and this patient would be left untreated.

Due to good response to antibiotic therapy, technical difficulty in obtaining SI joint fluid via aspiration for a confirmatory microbiological diagnosis and clear MRI findings, the patient was not subjected to any invasive investigations.

Upon the patient’s first admission for presumed PID, she was prescribed with analgesics. The analgesics masked her pain however did not treat her actual problem, i.e. infection and inflammation. After one year, she still had pain. Arthrodesis was offered but she was not keen mainly due to the risks of surgical complications and reduced SI joint range of motion post-surgery^[5] which was explained to her. For her, she was willing to endure pain than to compromise her current joint function.

If a person suffers from chronic pain, a vicious cycle typically exists. There will be anxiety, depression and sleep disturbances; among others. With one leading to another and if the cycle continues, that individual’s psychosocial life can be affected. For this young patient, she has to live with pain at an early age due to delayed treatment. These types of patients should be referred to pain specialists to help them cope better living with chronic pain. If her pain is managed well, she will have the potential to lose more weight. Losing weight can help improve pain caused by excessive weight burdening the SI joint. This patient will definitely benefit from a pain specialist.

Conclusion

Better understanding of disease matter, selection of right

disease detection tool and high index of suspicion are paramount to avoid misdiagnosis. Apart from medical/surgical treatment, management should be focused on improving patient's quality of life as some young patients; who were previously active and mentally healthy, may have movement limitations or psychosocial problems arising from chronic pain caused by this rare joint infection.

Acknowledgement

The author would like to thank the Director General of Health Malaysia for the permission to publish this article.

Conflict of Interest

The author declares no conflict of interest.

References

1. Schwabe C, Steinetz B, Weisse G, Segaloff A, McDonald Jk, O'byrne El, *et al.* Relaxin. In Proceedings of the 1977 Laurentian Hormone Conference. 1978; 1:123-211. Academic Press.
2. Woytala PJ, Sebastian A, Błach K, Silicki J, Wiland P. Septic arthritis of the sacroiliac joint. *Reumatologia*. 2018; 56(1):55.
3. Rashed R, Younis F. Methicillin Resistant Staphylococcus Aureus Sacroiliac Joint Septic Arthritis in an Adult Patient Treated with Daptomycin. *Journal of bone and joint infection*. 2017; 2(3):143.
4. Brusck JL. Septic Arthritis. *EMedicine*. 2005; 18:1-16.
5. Lindsey DP, Kiapour A, Yerby SA, Goel VK. Sacroiliac joint fusion minimally affects adjacent lumbar segment motion: a finite element study. *International journal of spine surgery*. 2015; 9:64.