



E-ISSN: 2707-8353

P-ISSN: 2707-8345

IJCRO 2024; 6(2): 34-36

[www.orthocasereports.com](http://www.orthocasereports.com)

Received: 19-07-2024

Accepted: 23-08-2024

**Rajesh Kumar Vemparala**  
Consultant Orthopaedic  
Surgeon, Athani Hospital,  
Nattukal-Athicode Road  
Near Kozhinjampara,  
Palakkad, Kerala, India

## Non-operative treatment of isolated bilateral clavicle fractures: A case report

**Rajesh Kumar Vemparala**

DOI: <https://doi.org/10.22271/27078345.2024.v6.i2a.219>

### Abstract

Clavicle fractures are among the most common fractures in adults. Bilateral clavicle fractures are uncommon injuries and are rarely reported in literature. Most of the studies prefer surgical management over conservative for bilateral clavicle fractures to achieve better functional outcome and early rehabilitation. We present a rare case of 68 year old female with bilateral clavicle fractures was treated non operatively. The follow up of this patient showed good functional outcome with full range of shoulder movements on either side and pain free.

**Keywords:** Bilateral clavicle fractures, case report, non-operative, functional outcome

### Introduction

Incidence of clavicle fractures constitutes 2.4-4% in all types of fractures <sup>[1]</sup>. Bilateral clavicle fractures is a rare injury comprising 0.43% of all clavicle fractures. Incidence of these fractures constitutes 0.011 to 0.017% <sup>[2]</sup>. Since it is a rare injury, there is no general consensus to treat these fractures surgically or non-surgically. We present a rare case of bilateral clavicle fractures treated non operatively.

### Case Report

A 68 year old female presented to OPD one day later with pain in both clavicle and shoulder following slab broken and fell over both shoulder at home.

On Examination: She is hemodynamically stable. Mild swelling and tenderness present over both clavicle. No skin tenting or prominence. The clinical diagnosis was made of bilateral clavicle fracture. There was no associated injuries. Chest and shoulder radiograph showed bilateral mid shaft clavicle fracture (Allman Group -1, Robinson Type 2B1) (Fig 1). As there was no skin tenting, it was planned to treat non operatively with broad arm sling applied to both shoulder. She was on regular follow up since then and skin tenting was checked.

At 6 weeks follow up radiograph showed fracture uniting (Fig. 2). She attained full range of shoulder movements, pain free and resumed to work (Fig. 3). At 8 months follow-up, there was no tenderness at fracture site. Radiograph showed clavicle fracture united (Fig. 4).

### Discussion

Clavicle provides the junction between chest and upper limb. It plays an important role in whole function of shoulder girdle. The bone is thinner at mid shaft as it is at junction of two opposite curves of clavicle. Most of the fractures of clavicle occurs at this junction <sup>[3,4]</sup>.

Bilateral clavicle fractures constitute 0.43% of all clavicle fractures. Usually these are associated with high velocity injuries. The mechanism sustaining bilateral clavicle fractures is different from unilateral clavicle fractures. Fall or direct trauma to shoulder usually causes unilateral clavicle fractures while bilateral clavicle fractures are often caused by compressive forces across both shoulder girdle and direct trauma to both clavicle <sup>[5]</sup>. Direct trauma on one side and subsequent fall on other side <sup>[6]</sup> may also causes bilateral clavicle fractures. An index of suspicious of associated injuries such as multiple rib fractures, fail chest, brachial plexus injury, pneumothorax, pneumoperitoneum, aortic dissection, scapula and spine fractures, pelvic fractures <sup>[2]</sup> should be rule out.

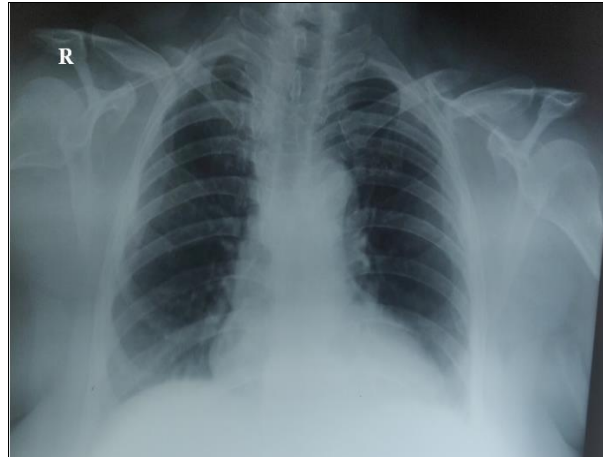
The traditional treatment of clavicle fractures is non operative <sup>[7]</sup>. Recently the literature reported a high rate of good functional outcomes with a low rate of non-union with non-operative treatment. No evidence of functional benefits resulting from surgery in comparison with non-operative treatment <sup>[8]</sup>.

**Corresponding Author:**  
**Rajesh Kumar Vemparala**  
Consultant Orthopaedic  
Surgeon, Athani Hospital,  
Nattukal-Athicode Road  
Near Kozhinjampara,  
Palakkad, Kerala, India

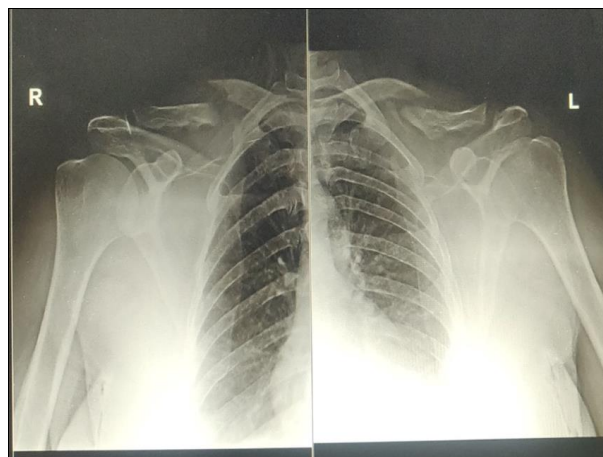
In a study by Schwarz *et al.* [9] Surgical treatment is necessary in cases with bilateral clavicle open fractures, Displaced fractures, communitated clavicle fractures, In young active patients. In a study by Puranik *et al.* [10] Operative treatment in bilateral clavicle fractures associated with multiple rib fractures allows better rehabilitation. Marya KM *et al.* [11] reported five cases of bilateral clavicle fractures associated with polytrauma was managed conservatively. The reported results at the end of 8 months were good, achieved good functional recovery and outcome.

A case report by Sutherland *et al.* [12] isolated bilateral clavicle fractures treated non operatively healed with better functional outcome.

We reported a rare case of 68 year old house wife presented with isolated bilateral clavicle fractures without associated injuries was treated non operatively. At 6 weeks follow up, there was no skin tenting and attained full shoulder range of movements. She was pain free and resume to her work. At 8 months follow up though there was a slight skin prominence at fracture site, radiograph showed fracture united.



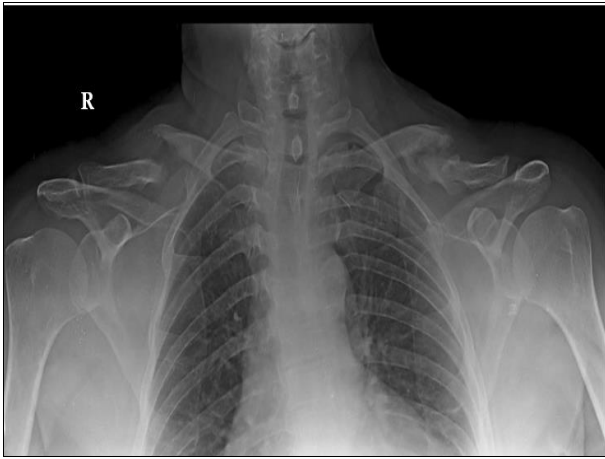
**Fig 1:** Chest radiograph showing bilateral clavicle fractures without associated injuries



**Fig 2:** Radiograph at 6 weeks follow up showed fracture uniting



**Fig 3:** At 6 weeks follow up, Clinical photograph showing bilateral clavicle fractures treated non operatively attained full range of shoulder movements



**Fig 4:** Radiograph at 8 months follow up showing fracture united

### Conclusion

Bilateral clavicle fractures are rare injuries. These are not commonly mentioned as an indication for operative intervention. Conservative treatment can improve better functional outcome in bilateral clavicle fractures without associated injuries. However operative treatment is an option in patients with polytrauma to restore early rehabilitation and functional outcome.

### Declaration of Competing Interest

The author declare no conflict of interest

### Source of Funding: Nil

### References

1. Postacchini F, Gumina S, De Santis P, Albo F. Epidemiology of clavicle fractures. *Journal of shoulder and elbow surgery*. 2002 Sep 1;11(5):452-426.
2. Van den Bout HE, Snyckers CH. Bilateral clavicle fractures: a case report and review of the literature. *Sa Orthopaedic Journal*. 2011 Jan;10(2):56-66.
3. Rowe C. An Adults of anatomy and treatment of mid-clavicular fractures. *Clin. Orthop*. 1968;58:43-50.
4. CM R. Fractures of the clavicle in the adult-epidemiology and classification. *J Bone Joint Surg, B*. 1998;80:476-484.
5. Owen E. A Case of simultaneous fracture of both clavicles. *The Lancet*. 1890 Jul 5;136(3488):19-20.
6. Wilson MJ. Bilateral fracture of the clavicle: report of an atypical case. *JBJS*. 1931 Jul 1;13(3):564-565.
7. Charles S Neer II Fractures of the distal third of the clavicle. *Clinical Orthopaedics and Related Research (1976-2007)*. 1968 May 1;58:43-50.
8. Zenni Jr EJ, Krieg JK, Rosen MJ. Open reduction and internal fixation of clavicular fractures. *JBJS*. 1981 Jan 1;63(1):147-151.
9. Schwarz N, Höcker K. Osteosynthesis of irreducible fractures of the clavicle with 2.7-MM ASIF plates. *Journal of Trauma and Acute Care Surgery*. 1992 Aug 1;33(2):179-183.
10. Puranik G, Gillham N. Bilateral fractured clavicles with multiple rib fractures. *Emergency Medicine Journal*. 2007 Sep 1;24(9):675.
11. Marya KM, Yadav V, Kochar H. CASE REPORT Bilateral clavicle fractures. *Hong Kong Journal of Orthopaedic Surgery*. 2002;6(1):39-41.

12. Sutherland AG, Knight DJ. Bilateral fractured clavicles: a pair of cases. *Acta orthopaedica belgica*. 2000;66(3):306-307.

### How to Cite This Article

Vemparala RK. Non-operative treatment of isolated bilateral clavicle fractures: A case report. *International Journal of Case Reports in Orthopaedics*. 2024;6(2):34-36.

### Creative Commons (CC) License

This is an open access journal, and articles are distributed under the terms of the Creative Commons Attribution-NonCommercial-ShareAlike 4.0 International (CC BY-NC-SA 4.0) License, which allows others to remix, tweak, and build upon the work non-commercially, as long as appropriate credit is given and the new creations are licensed under the identical terms.