



E-ISSN: 2707-8353
P-ISSN: 2707-8345
IJCRO 2020; 2(2): 61-63
Received: 01-05-2020
Accepted: 03-06-2020

Dr. Bhavya B Shah
Orthopaedic Consultant,
Harikrupa Hospital,
Ellisbridge, Ahmedabad,
Gujarat, India

Dr. Jyotindra P Pandit
Director and Orthopaedic
Consultant, Harikrupa
Hospital, Ellisbridge,
Ahmedabad, Gujarat, India

Dr. Prakash V
Director and Orthopaedic
Consultant, Harikrupa
Hospital, Ellisbridge,
Ahmedabad, Gujarat, India

Tubercular tenosynovitis of peroneal tendon sheath: An uncommon diagnosis

Dr. Bhavya B Shah, Dr. Jyotindra P Pandit and Dr. Prakash V

DOI: <https://doi.org/10.22271/27078345.2020.v2.i2b.28>

Abstract

Tuberculous Tenosynovitis of Peroneal Tendon Sheath is an uncommon diagnosis for foot swellings. Mycobacterium Tuberculosis in Foot and ankle accounts for less than 10% of total Musculoskeletal Tuberculosis. It affecting the tendon sheath only is not so common and the reported cases of peroneal sheath tuberculosis tenosynovitis are very few as per literature. Hereby, we present a case report of Tuberculous Tenosynovitis of peroneal tendon sheath.

Keywords: Mycobacterium tuberculosis, peroneal tendon sheath tenosynovitis

Introduction

Introduction

Mycobacterium Tuberculosis of peroneal sheath is an uncommon presentation found in clinical set-up. Here we present a case of Tubercular tenosynovitis of peroneal sheath.

Case Report

18 year old male patient presented to our clinic with complains of pain and swelling over left ankle since 3 months associated with low grade fever and weight loss. On examination, localized swelling on lateral aspect of calcaneo-cuboid joint. Swelling was also present on the medial aspect of plantar aspect of right foot obliterating the medial longitudinal arch which was present on the opposite side. Ankle movements were normal but eversion of foot was painful. Systemic Examination revealed swelling over neck and one of his finger. Chest examination was found to be normal. Pre-operative Work up was done. Tests for immunocompromised state were negative.

MRI images

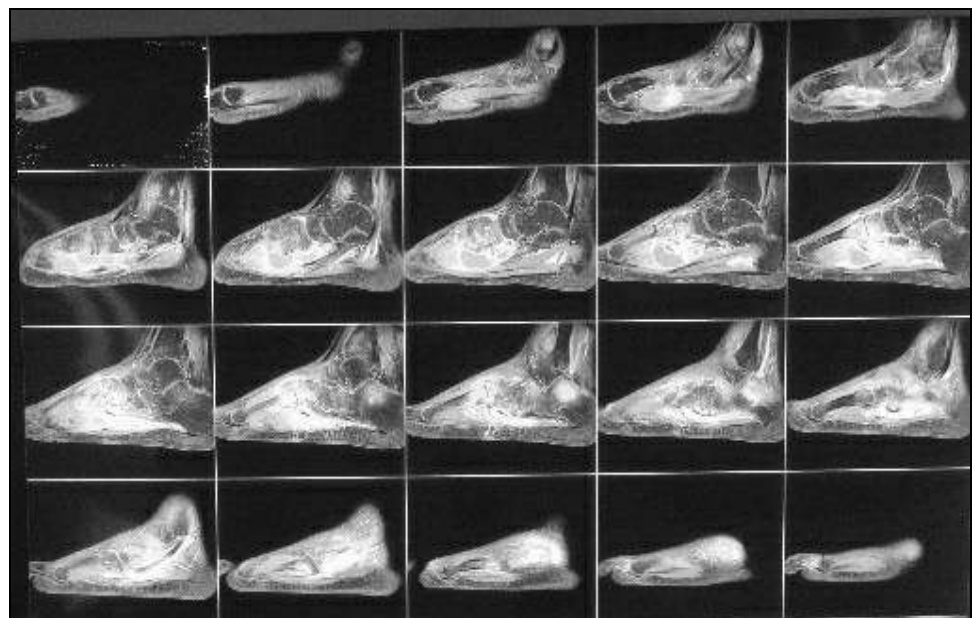


Fig 1: Saggital section showing the extent of disease

Corresponding Author:
Dr. Bhavya B Shah
Orthopaedic Consultant,
Harikrupa Hospital,
Ellisbridge, Ahmedabad,
Gujarat, India

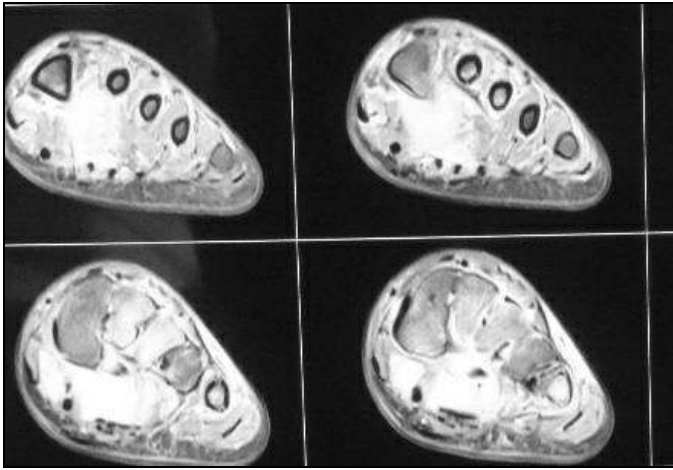


Fig 2: Axial cut

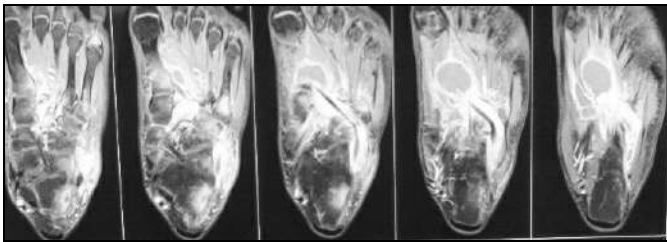


Fig 3: Coronal cut

Looking at the severity of pain, we decided to drain the swelling and take tissue biopsy. Based on MRI pictures, collection was thought to have its presence along the sheath of the peroneus longus tendon extending from the base of 1st metatarsal and medial cuneiform to behind the lateral malleolus.

Operative Procedure

Under Spinal Anaesthesia in supine position without tourniquet control, incision was placed over calcaneo-cuboid joint. Pus collection with rice bodies was drained. Fluid was sent for culture. Peroneal sheath was opened and traced along its tract.

Peroneal tendon was found thickened and sheath was inflamed and stuck with inflammatory exudates. Disc forceps were used to get the synovial biopsy and the material was sent for histopathology.

Instruments passed along the tendon could be felt on the plantar aspect beneath the 1st metatarsal. Separate incision was made along medial aspect of 1st metatarsal and medial cuneiform.

Proper saline wash was given on both sides. Instruments passed on both ends could meet on the plantar aspect suggesting that collection was along the line of peroneus longus sheath.

Drain was placed and closure was done. Limb was immobilized with below ankle posterior slab for 6 weeks. Histopathology report was suggestive of chronic granulomatous infection with positive acid-fast bacilli.

Anti-Tuberculosis treatment as per revised National Tuberculosis Control Programme for Osteoarticular TB with isoniazid (H), rifampicin (R), pyrazinamide (Z) and ethambutol (E) for 2 months and Isoniazid and rifampicin for 4 months was advised.

9 month follow-up shows that the infection has been controlled with no recurrence.

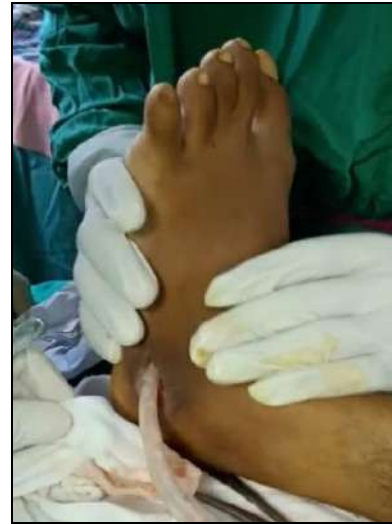

Fig 4: Lateral incision over lateral aspect of calcaneo-cuboid joint

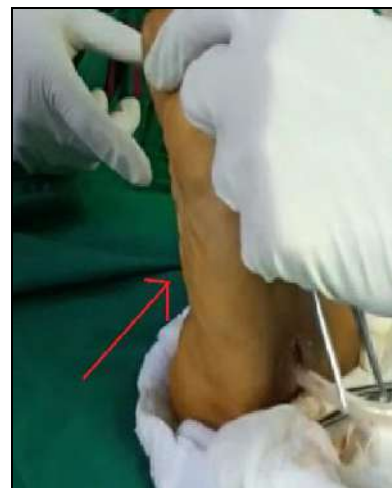

Fig 5: Suction catheter passed through the lateral incision and can be seen touch the planar aspect of medial half of foot

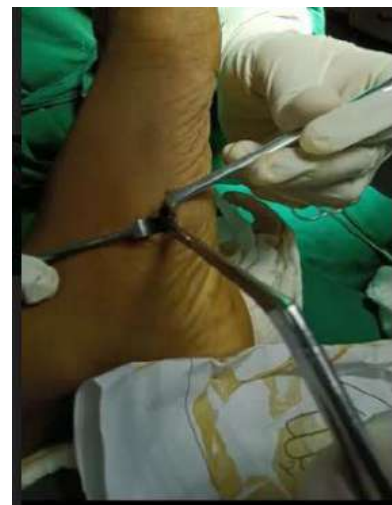

Fig 6: Medial incision along base of 1st metatarsal and medial cuneiform

Discussion

Mycobacterium Tuberculosis in Foot and ankle accounts for less than 10% of total Musculoskeletal Tuberculosis [1]. It affecting the tendon sheath only is not so common and the reported cases of peroneal sheath tuberculosis tenosynovitis are very few as per literature [2, 3, 4].

The disease is classified into three stages: the earliest hygromatous form, a serofibrinous form, and a fungoid form. The hygromatous form has normal appearing tendon sheath with serous exudates. As the infection evolves, the serofibrinous form appears as occlusion of the tendon sheath with fibrous tissue and caseous inflammatory debris. Granulation tissue is seen in this stage. Synovial sheath has presence of Rice Bodies. The fungoid stage is characterized by excessive granulation tissue and cold abscess and sinus tract formation occurs in this stage [4,5].

Our case presented at the serofibrinous stage as demonstrated by the presence of fibrotic inflamed synovium and rice bodies during the operation.

The diagnosis of this case was based on the presence of caseation and Langhan giant cells and acid-fast bacilli testing positive with Ziehl-Neelsen stain in the histological specimen although the tuberculosis culture was negative.

Extrapulmonary Tuberculosis can be diagnosed by following criteria:

- 1) biopsy material showing evidence of caseating granuloma in gross pathology and sometimes positive acid-fast bacilli on histology specimen
- 2) evidence of Mycobacterium Tuberculosis in culture medium

Conclusion

In conclusion, although tuberculosis is an uncommon cause of tenosynovitis, particularly in the foot, it should be included in the differential diagnosis of patients suffering from persistent swelling and pain in the hind foot, especially in countries where tuberculosis is prevalent.

References

1. SM Tuli. 4th Edition. New Delhi: Jaypee Brothers Medical Publishers; 2010. Tuberculosis of the skeletal system; pp. 187–90. [Google Scholar] [Ref list].
2. Ajoy SM, Samorekar B, Soman S, Jadhav M. Isolated Tuberculous Peroneal Tenosynovitis: A Case Report. *J Clin Diagn Res.* 2015; 9(7):RD01–RD2. doi:10.7860/JCDR/2015/14081.6212
3. KP Raju, J Mohan Kumar, R Shetty. Tuberculous tenosynovitis of ankle with rice bodies. *Foot and Ankle Online Journal.* 2013; 6(10). [Google Scholar] [Ref list]
4. Tuberculous peroneal tenosynovitis. A case report. Abdelwahab IF, Kenan S, Hermann G, Klein MJ, Lewis MM *J Bone Joint Surg Am.* 1993; 75(11):1687-90.[PubMed] [Ref list]
5. Sanders CJ, Schucany WG. Tuberculous tenosynovitis. *Proc (Bayl Univ Med Cent).* 2008; 21:71e2.