International Journal of Case Reports in Orthopaedics

**E-ISSN:** 2707-8353
**P-ISSN:** 2707-8345
IJCRO 2021; 3(2): 24-27
Received: 13-05-2021
Accepted: 15-06-2021

**Dr. Sinukumar Bhaskaran**
Department of Orthopaedics, Columbia Asia Hospital Kharadi, Pune, Maharashtra, India

**Dr. Lalkar Laxman Gadod**
Department of Orthopaedics, Columbia Asia Hospital Kharadi, Pune, Maharashtra, India

**Dr. Azhar Lakhani**
Department of Orthopaedics, Columbia Asia Hospital Kharadi, Pune, Maharashtra, India

**Dr. Tasneem Kapadia**
Department of Orthopaedics, Columbia Asia Hospital Kharadi, Pune, Maharashtra, India

**Dr. Mayank Pathak**
Department of Orthopaedics, Columbia Asia Hospital Kharadi, Pune, Maharashtra, India

**Corresponding Author:**
**Dr. Lalkar Laxman Gadod**
Department of Orthopaedics, Columbia Asia Hospital Kharadi, Pune, Maharashtra, India

# Hinged knee arthroplasty in a case of non-union distal femur fracture with implant failure in an elderly individual: A case report

**Dr. Sinukumar Bhaskaran, Dr. Lalkar Laxman Gadod, Dr. Azhar Lakhani, Dr. Tasneem Kapadia and Dr. Mayank Pathak**

**DOI:** https://doi.org/10.22271/27078345.2021.v3.i2a.62

**Abstract**
**Introduction:** Distal femur fractures are one of the most common fractures accounting for 0.5% of all fractures with incidence of about 7/100000/year. Majority of the fractures occur in elderly population (above 60 year) with osteoporosis resulting from a low energy trauma. In the younger age group these fractures are associated with high energy trauma.
**Case report:** A 68-year-old male presented with chief complaints of pain and deformity in right knee since 1 year. The patient had a history of distal femur fracture 2 years back for which he was operated twice with distal femur plating and bone grafting. The patient was a known case of diabetes mellitus on medication since 5 years. Radiographs of the right knee in anteroposterior and lateral views were taken, which showed distal femur fracture non-union with a broken locking compression plate with grade 4 knee arthritis. Due to the failure of osteosynthesis twice, and the patient demanding for early mobilization, a single staged procedure with implant removal followed by an arthroplasty using cemented modular distal femur endoprosthesis was planned for the patient.
**Conclusion:** Hinged knee arthroplasty can be considered as a treatment option for patients with distal femur non-union with pre-existing severe knee arthritis. It helps in early weight bearing and return to activities of daily living.

**Keywords:** distal femur endoprosthesis, non-union distal femur fracture, implant failure

## Introduction

Distal femur fractures are one of the most common fractures accounting for 0.5% of all fractures with incidence of about 7/100000/year. Majority of the fractures occur in elderly population (above 60 year) with osteoporosis resulting from a low energy trauma. In the younger age group these fractures are associated with high energy trauma [1].

Non-union of the distal femur fracture is a rare entity which occurs due to poor bone quality, comminuted fracture pattern, improper fixation and associated comorbidities. The associated bone loss and soft tissue scarring poses a challenge in the management of the distal femur fracture non-union. The treatment options available for these patients includes condyle plate, intramedullary nail, open reduction and internal fixation (ORIF), blade plate and cannulated cancellous screw fixation [2].

Despite the available options, osteosynthesis of these fractures is associated with complications of non-union, implant failure, and mal-reduction, because of poor metaphyseal bone stock available. Further, pre-existing knee arthritis in elderly patients may require secondary operative procedures for the same.

Distal femur fractures in elderly patients with associated non-union can be managed with an arthroplasty using cemented modular distal femur endoprosthesis [3].

Primary total knee replacement for the treatment of distal femur non-union fracture is a challenging procedure due to distorted anatomy, poor bone stock, previous incisions and scarring which pose problems in approach, exposure, patellar eversion and stability.

Also, in view of previous hardware, risk of infective non-union has to be ruled out.

The newer improved implant designs has made it possible to perform these surgeries with minimal complications.

## Case report

A 68-year-old male presented with chief complaints of pain and deformity in right knee since 1 year. The patient was apparently alright 1 year back when he developed pain in right knee

which was insidious onset, gradually progressive, dull aching in nature, aggravated by movement and walking, relieved with medication and rest.

The patient had a history of distal femur fracture 2 years back for which he was operated twice with distal femur plating and bone grafting. The patient was a known case of diabetes mellitus on medication since 5 years.

The patient was disabled due to inability to weight bear on that limb and severe stiffness. On inspection a 15 cm well healed scar mark of previous surgery was noted over the anterior aspect of right knee. On palpation, tenderness was present over the supracondylar femur region.

Further examination revealed flexion deformity of 15 degree with flexion possible up to 30-degree. (Fig 1a, b, c)

a b c

**Fig 1 a, b, c:** Preoperative clinical pictures showing previous scar mark of surgery (a), knee range of motion (b, c)

Radiographs of the right knee in anteroposterior and lateral views were taken, which showed distal femur fracture non-union with a broken locking compression distal femur plate with grade 4 knee arthritis. (Fig 2)


**Fig 2:** Preoperative xray AP and lateral view showing distal femur non-union with broken locking compression distal femur plate

Due to the failure of osteosynthesis twice, with the patient demanding for early mobilization and weight bearing, single staged procedure with implant removal followed by an arthroplasty using cemented modular distal femur endoprosthesis was planned for the patient. CBC, ESR, CRP values was within normal range.

After obtaining the fitness for surgery, the patient was operated in supine position under spinal anaesthesia using medial parapatellar approach. In view of repeated surgeries, the extensor mechanism was contracted which led to difficulty in patellar eversion, hence a quadriceps snip was done to aid in exposure.

The broken implant was removed and followed by resection of the distal femur below the fracture site taking due care not to damage the surrounding neurovascular bundle. Intramedullary reaming was done and the femoral canal was prepared for stemmed implant. Proximal tibial cut was done using extramedullary jig. Trial implant were placed followed by checking stability, range of motion and patellar tracking. A cemented hinged total knee arthroplasty using RESTOR (Syncera Smith and Nephew) implant femoral component with pivot pin and retaining ring, and the tibial component with split bushes and bumper and curved intramedullary stem of size 12 mm. (Fig 3a, b, c and fig 5 a, b) Intraoperatively, there was partial peel off of patellar tendon from the tibial tuberosity which was fixed using a CC screw and non-absorbable ethibond (No.5). (Fig 4)

a b c

**Fig 3 a, b, c:** Intraoperative pictures showing broken plate with non-union distal femur (a), resected distal femur with Implant (b), and after removal of plate and distal femur(c)

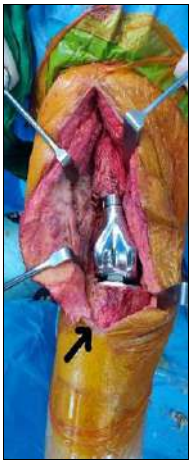

**Fig 4:** Intraoperative complication showing peel off of patellar tendon

a b

**Fig 5 a, b:** Immediate posterative AP and latreal view showing cemented hinged total knee replacement with CC screw fixation for patellar tendon

Further release of quadriceps was done by pie crusting technique and lateral parapatellar release to achieve an on-table flexion up to 90 degrees.

After the prosthesis implantation, stability, patellar tracking and range of motion was checked intraoperatively. Wound was closed in layers. Postoperatively, the knee was maintained in extension using a long knee brace. Continuous passive motion of 0-45 degree and isometric quadriceps strengthening exercises started day after surgery. Partial weight-bearing started immediately on post op day 1 using a long knee brace. Full weight bearing was initiated after 6 weeks after check x-ray.

Three months post-operatively, the knee radiographs showed no signs of osteolysis and subsequent implant loosening. (Fig 6 a and b) The outcome at 8 months was good with patient having good knee range of movements (0-90 degree of flexion with extension lag) and no pain on weight-bearing. (Fig7a, b, c) The patient is comfortable with no pain and difficulty in walking. The oxford knee score pre-operatively was18 and after 8 months of follow up was 42. We accept shorter follow-up period is the limitation of this case report.

a b

**Fig 6 a, b:** 8 months follow up x-rays showing no signs of osteolysis and subsequent implant loosening

a b c

**Fig 7 a, b, c:** 3 months follow up clinical pictures showing good ROM and healed operative scar mark

## Discussion

Distal femur fractures are one of the most common fractures, accounting 0.5% of all fractures [1]. Distal femur non-union fracture is a challenging fracture to treat because they are associated with bone loss and soft tissue scarring. The treatment options available for these fractures includes condyle plate, intramedullary nail, open reduction and internal fixation (ORIF), blade plate and cannulated screw fixation [2]. Another available option for the management of distal femur fractures in elderly patients with associated

non-union is primary total knee replacement (TKR) using cemented modular distal femur endoprosthesis for fractures associated with arthritic deformity which helps in early mobilization and weight-bearing [3].

Appelton p *et al.* reported their experience of treating 54 patients with non-union distal femur fracture using constrained knee prosthesis [4], In their study, they concluded that using constrained knee prosthesis offered an alternative treatment to internal fixation in selected elderly patients with distal femur fracture, with a high probability of survival in the patients into whom constrained knee prosthesis was implanted.

Li R *et al.* [5] in their study, systematically reviewed articles which reported indication, techniques, implants, outcome and complication of total knee arthroplasty for acute distal femur fracture, and they concluded that modular constrained implants may be appropriate for comminuted intra-articular fractures, whereas extra-articular fractures may be sufficiently managed with unconstrained implants supplemented with fracture fixation. As in our case the patient was a chronic case.

Girgis E *et al.* [6] reported their experience of treating 14 patients with type III periprosthetic distal femur fracture using hinge knee prosthesis. They concluded that revision knee distal femoral replacement is an appropriate method to treat elderly patients who sustained periprosthetic type III distal femoral fractures in association with poor bone stock, caused by osteoporosis and/or comminution. As in our case the patient was twice previously treated with ORIF with bone grafting.

Neal DC *et al.* [7] reported their experience of a case of traumatic left open periprosthetic distal femur fracture with right closed intraarticular distal femur fracture with end stage arthrosis treated with single staged distal femur replacement, they concluded that single stage distal femur replacement provides the benefits of early mobilization and accelerated recovery in intraarticular distal femur and periprosthetic fractures.

Stambaugh JB *et al.* [8] reported 3 cases of revision total knee arthroplasty using tapered modular fluted titanium stem. They concluded that these stems hold promise to achieve stable fixation in revision total knee arthroplasty where host meta-diaphyseal bone is deficient.

Sawant MR *et al.* [9] reported 4 cases of non-union proximal tibial stress fractures with deformed arthritic knees, treated with a modular total knee prosthesis with a long tibial stem extension. They concluded that modular total knee prosthesis suitable for patients with proximal tibial stress fracture non-union with arthritic knee joint, since it corrects the deformity and adverse biomechanics at the fracture site while stabilizing the fracture and treating the arthritic joint. In our case as well as a result of arthritis there was a constant eccentric forces across the fracture site which may have led to the repeated non-union. Hence addressing the arthritis with a distal femoral replacement simultaneously improved the outcome. The patient was thus planned for primary total knee replacement using cemented modular distal femur endoprosthesis was planned for the patient.

## Conclusion

Distal femoral knee replacement can be considered as a treatment option for patients with supracondylar femur non-union with pre-existing severe knee arthritis. It helps in early weight bearing and return to activities of daily living.

## References


1. Elsoe R, Ceccotti AA, Larsen P. Population-based epidemiology and incidence of distal femur fractures. International orthopaedics 2018;42(1):191-6.
2. Ebraheim NA, Martin A, Sochacki KR, Liu J. Nonunion of distal femoral fractures: A systematic review. Orthopaedic surgery 2013;5(1):46-50.
3. Rajasekaran RB, Palanisami DR, Natesan R, Jayaramaraju D, Rajasekaran S. Megaprosthesis in distal femur non-unions in elderly patients—experience from twenty four cases. International orthopaedics 2020;44(4):677-84.
4. Appleton P, Moran M, Houshian S, Robinson CM. Distal femoral fractures treated by hinged total knee replacement in elderly patients. The Journal of bone and joint surgery. British volume 2006;88(8):1065-70.
5. Li R, Lall A, Schwechter EM. Primary total knee arthroplasty for distal femur fractures: a systematic review of indications, implants, techniques, and results. Am J Orthop 2017;46(3):E163-71.
6. Girgis E, McAllen C, Keenan J. Revision knee arthroplasty using a distal femoral replacement prosthesis for periprosthetic fractures in elderly patients. European Journal of Orthopaedic Surgery & Traumatology 2018;28(1):95-102.
7. Neal DC, Sambhariya V, Tran A, Rahman SK, Dean TJ, Wagner RA, Sanchez HB. Single-stage bilateral distal femur replacement for traumatic distal femur fractures. Arthroplasty today 2019;5(1):26-31.
8. Stambough JB, Mason JB, Riesgo AM, Fehring TK. Tapered modular fluted titanium stems for femoral fixation in revision total knee arthroplasty. Arthroplasty today 2018;4(1):3-9.
9. Sawant MR, Bendall SP, Kavanagh TG, Citron ND. Non-union of tibial stress fractures in patients with deformed arthritic knees: treatment using modular total knee arthroplasty. The Journal of bone and joint surgery. British volume 1999;81(4):663-6.